Rearfoot and Ankle

Jennifer Van, DPM

Department of Surgery,

Temple University School of Podiatric Medicine

Previous versions attributed to Andrew Meyr, DPM, Joshua Moore, DPM & Bronwyn Wilkie, DPM

I. Posterior Heel Pain

II. Pes Plano Valgus

III. Cavus Foot

IV. Arthrodesis of the Hindfoot

V. Ankle Conditions

VI. Supramalleolar considerations

The Foundation

Posterior Heel Pain

- Differential Diagnosis:
  - Inflammatory
  - Rhuematoid
  - Traumatic
  - Neurologic
  - Sever's Disease
  - Insertional Achilles Tendonitis
  - Posterior calcaneal spur
  - Haglund's Deformity

The Goldfarb Foundation

Posterior heel pain

Posterior heel spur

- Insertional achilles tenderness
- Pain all the time especially with resisted plantarflexion
- Inflamed posterior heel

Haglunds Deformity

- Posterolateral heel tenderness
- Pain in shoe gear
- Inflamed posterolateral heel

The Goldfarb Foundation

Posterior heel radiographs

- Plain films to rule out trauma and tumor and assess alignment

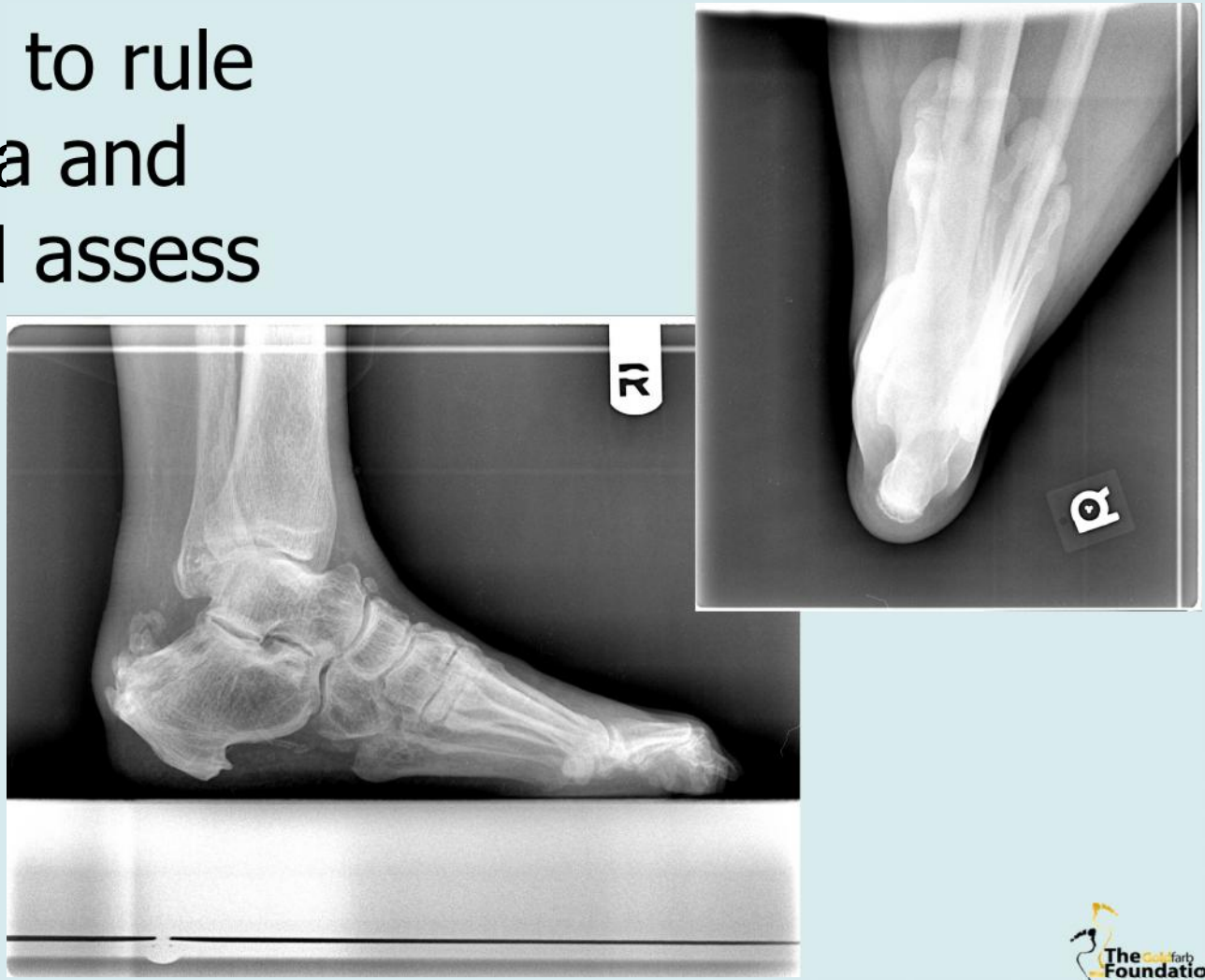

Lateral Projection Cont.

- 1. Fowler-Phillip Angle (normal=44-69°): Intersection of line tangent to posterosuperior prominence and line tangent to anterior tubercle and and medial process of posterior tuberosity. 75° is pathologic.
- Total Ankle (Vega): Sum of Fowler-Phillip and Calcaneal Inclination Angle. Pathologic is 90°.

Posterior heel pain-Surgical intervention

Posterior Heel Pain

- Resection without achilles detachment
- Resection with achilles detach/reattach
- Consider posterior muscle group lengthening

Haglund's Deformity

- Resection of posterosuperior calcaneal border
- Keck and Kelly osteotomy

The Goldfarb Foundation

Posterior Heel Pain

- Posterior calcaneal spur resection
  - Prone position
  - Spur resection – osteotomes, power rasp, c-arm
  - Achilles detach/reattach pending investment of the tendon
  - Post op protected weight bearing 4-8 weeks pending adjunct procedures

Posterior Heel Pain

- Haglunds resection
  - Prone or lateral position
  - Simple exostectomy – osteotomes, power rasp

Keck and Kelly – resection of dorsal base wedge from the posterior calcaneus, avoid posterior facet of STJ, through and through medial-lateral, preferable maintain plantar cortex. Staple fixation

Flatfoot

Pes Plano valgus

Flexible flatfoot etiology

- Ligamentous laxity (Downs, Ehler's-Danlos, Marfans)
- Enlarged or accessory navicular
- Biomechanical (Equinus, forefoot varus/valgus, muscle imbalance, hypermobile 1st ray, torsional abnormalities)
- Neurotrophic feet (early stages)
- Limb length discrepancy (long leg)

The Goldfarb Foundation

Rigid flatfoot etiology

- Vertical talus
- Tarsal coalition/peroneal spastic flatfoot
- CP
- Spina bifida
- Post traumatic
- arthrogryposis

PTTD Radiographic evaluation

- 3 standard foot views
- Calcaneal axial and Harris Beath projections
    - STJ coalitions, calcaneal alignment
- Stress dorsiflexion/charger images
    - TEV, vertical talus
- Ankle images

Normal AP Projection

- Kite's Angle – Talocalcaneal angle 20-40=normal
- Talonavicular congruence
- Cuboid abduction angle – 0-5 = normal

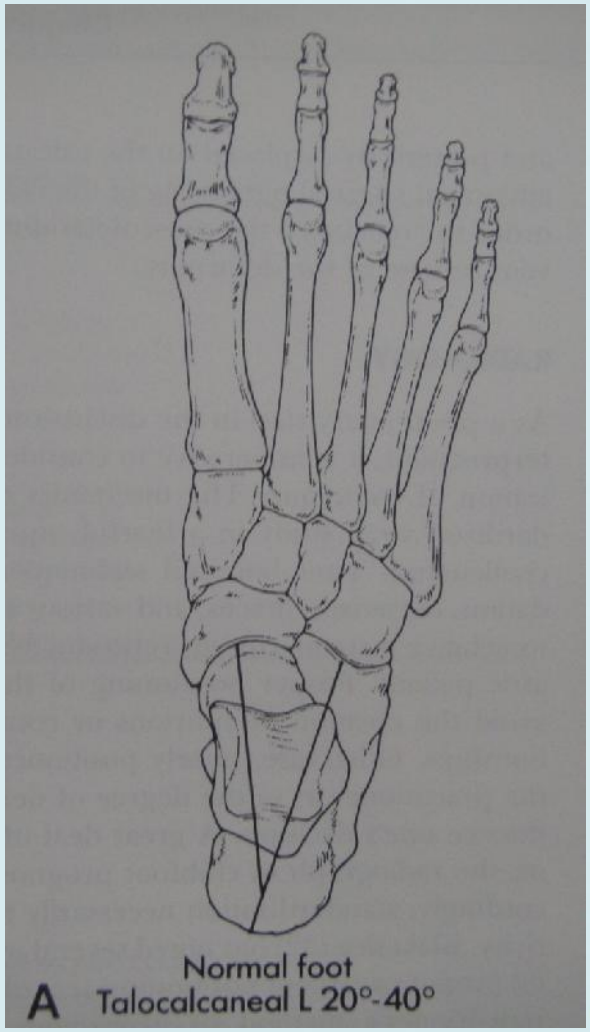

Normal Lateral Projection

- Calcaneal Inclination Angle 18-21°: Sagittal positioning of inferior surface of the calcaneus to floor.
- Talar Declination Angle 21°: Relationship between axis of talar head and neck to the floor.
- Talocalcaneal Angle 15-35°: Compares the long axis of the head and neck of the talus to the inferior surface of the calcaneus.
- Sinus Tarsi: obliterated in pronated foot.

PTTD Radiographic alterations

- DP Images
  - AP Kite's angle>20 degrees
  - C-C >5 degrees
  - Decreased T-N congruency
- Lat Images
  - Increase in Talar declination
  - Navic-cun breach
  - Decreased calcaneal inclination
- Calcaneal axial and medial oblique for coalitions


L


R

Surgical Intervention Basic Principles

- Control pain
- Limit Progression
- Flexible flatfoot – joint sparing procedures
- Rigid flatfoot – arthrodesis
- Always consider TAL/gastroc recession

The Goldfarb Foundation

Flatfoot - PTTD

Pre-surgical considerations

- Available ROM - Flexible versus Rigid
- Planal dominance (x-ray and clinical)
- Growth plates
- Related medical conditions
- Superstructural deforming forces (equinus, tibial torsion, etc.)
- Not controllable by mechanical devices
- Presence of secondary changes - DJD

The Goldfarb Foundation

Equinus

- Silverskiold test
- Equinus with knee straight, relieved when bent – gastroc recession
- Equinus with knee bent and straigth - TAL

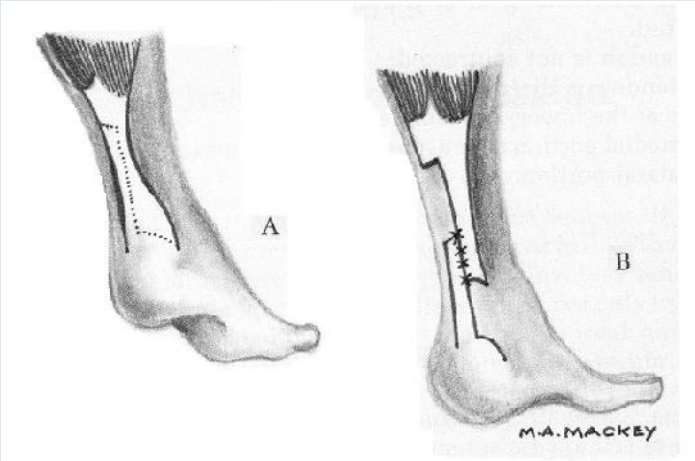

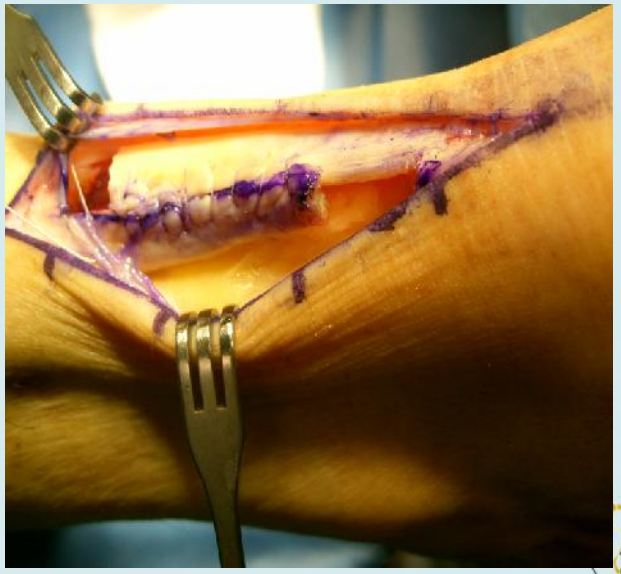

Pes Planus - Medial Column Procedures

- Kidner Remove hypertrophied/accesory navic; transpose PTT insertion to plantar navicular
- Cotton
- Lapidus
- FDL Transfer

Pes Planus - Medial Column Procedures

- Cotton: opening wedge osteotomy of the medial cuneiform

The Goldfarb Foundation

Pes Planus – Medial column procedures

- Cotton
  - Tricortical wedge, plates? Surgeon preference
  - Corrects sagittal plane deformity
  - Over correction leads to dorsal midfoot exostosis and sesamoiditis
  - NWB until radiographic incorporation of the graft – 6-12 weeks

Pes Planus - Medial Column Procedures

- Lapidus: 1st metatarso-cuneiform arthrodesis

Pes Planus - Medial Column Procedures

- FDL Transfer: transect FDL proximal to knot of Henry and attach to navicular
  - Use for correctable deformity, triplanar correction

Pes Planus - Medial Column Procedures

- Lowman: TAL; T-N arthrodesis; reroute tib ant under navicular to spring lig; medial arch tenodesis with slip of the achilles
  - Sagittal plane correction
  - NWB 6-8 weeks for bony union

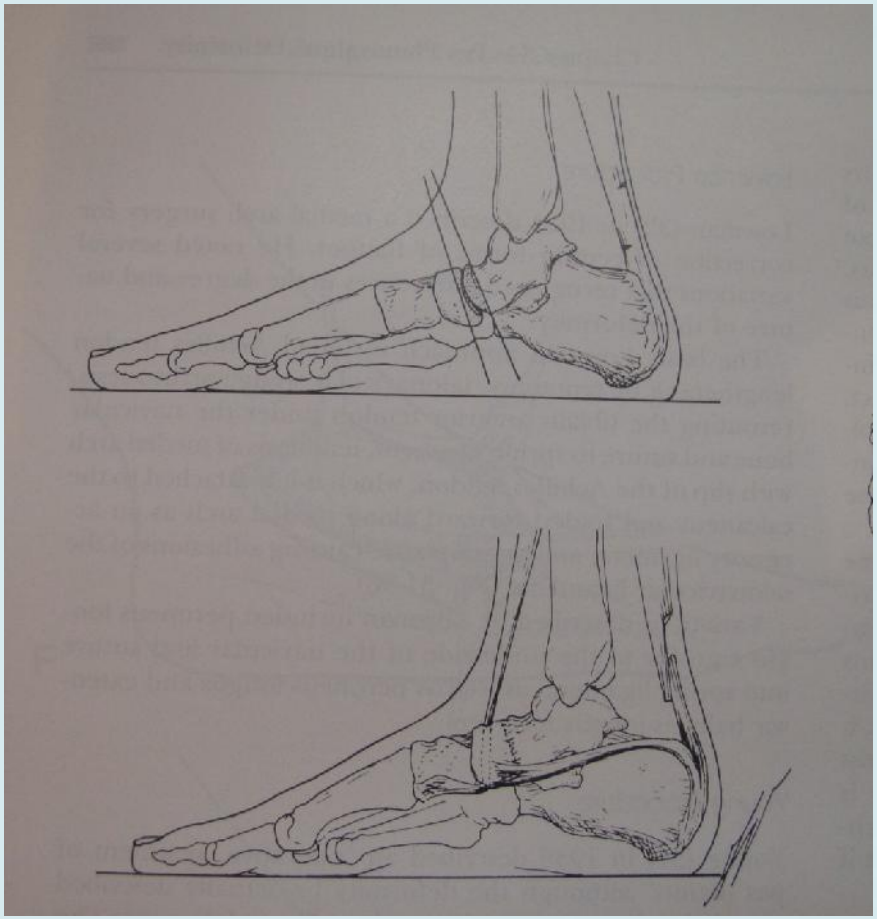

Pes Planus - Medial Column Procedures

- Young Tenosuspension: TAL; reroute tib ant through slot in the navicular; transpose PTT insertion to plantar navicular
  - Triplanar correction
  - NWB 4 wks for soft tissue healing

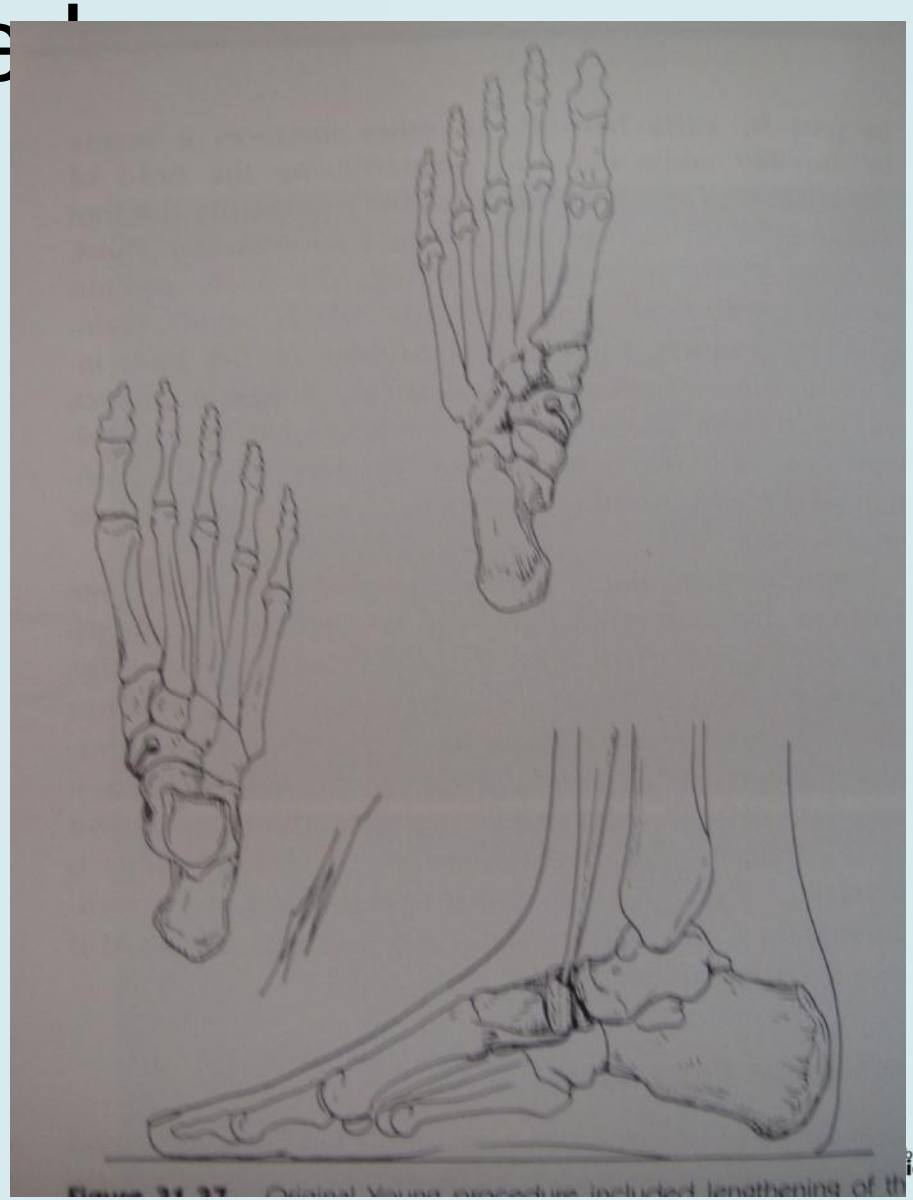

Pes Planus - Medial Column Procedures

- Hoke: TAL; naviculo-cuneiform arthrodesis
  - Sagittal plane correction
  - NWB 6-8 weeks for bony union

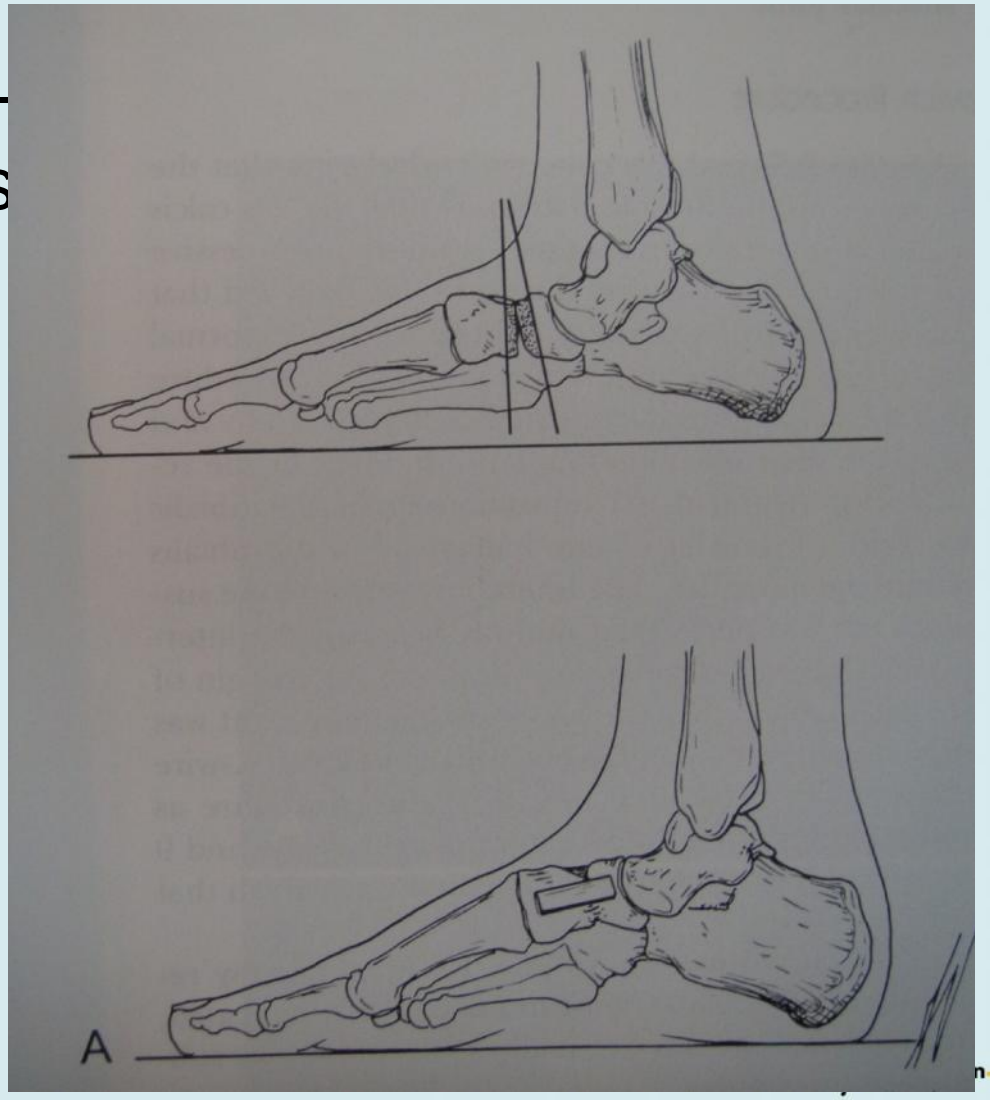

Pes Planus - Medial Column Procedures

- Miller: TAL; 1st met-medial cuneiform-navicular arthrodesis; advancement of the PTT insertion and spring lig
  - Sagittal plane correction
  - NWB 6-8 wks for bony union

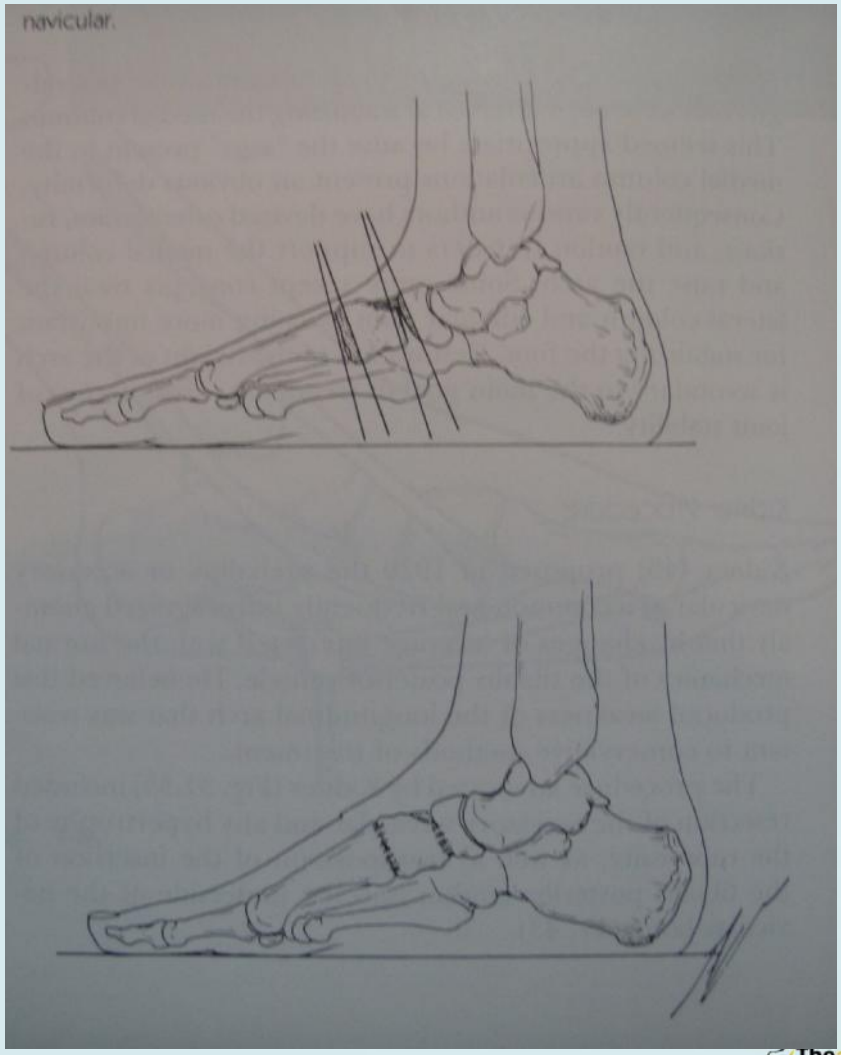

Pes Planus - Calcaneal osteotomies

- Evans
- Koutsogiannis
- Dwyer
- Gleich
- Silver

Pes Planus - Calcaneal Osteotomy

- Evans: opening wedge of the anterior calcaneus 1.5cm proximal to the c-c joint

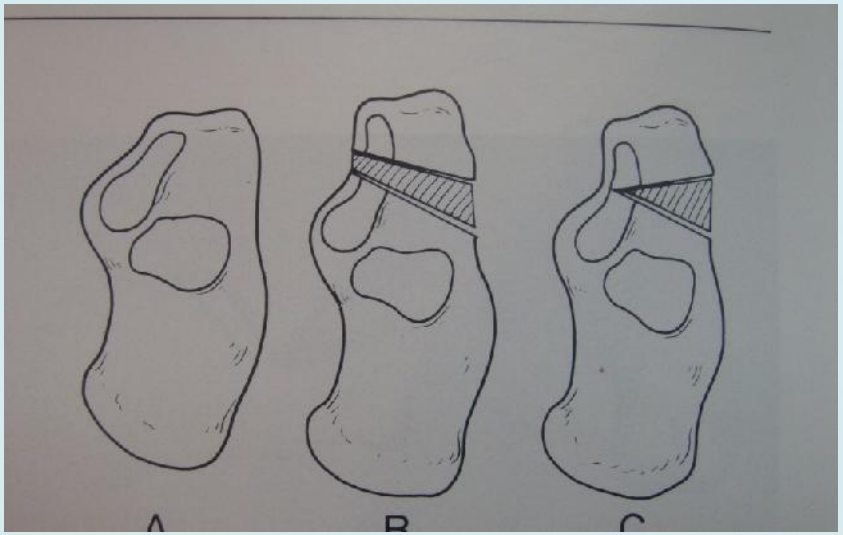

Pes Planus – Calcaneal Osteotomies

- Evans
  - Incision oblique over c-c joint, avoid sural nerve
  - Reflect EDB and retain dorsal c-c ligaments
  - Transverse plane correction – watch for metatarsus adductus

Pes Planus - Calcaneal Osteotomy

- Koutsogiannis: medial displacement posterior calcaneal osteotomy
  - Oblique lateral incision avoiding peroneal tendons and sural nerve
  - Maintains achilles and plantar fascial attachments
  - Washer increases surface area of screw contact

Pes Planus - Calcaneal Osteotomy

- Koutsogiannis
  - Frontal plane correction
  - Increases supinatory force of the achilles tendon
  - Screw irritation is common

Pes Planus - Calcaneal Osteotomy

- Dwyer: Mid body closing wedge osteotomy
- Medial base wedge for planus foot
- Frontal plane correction
- Increases supinatory force of the achilles

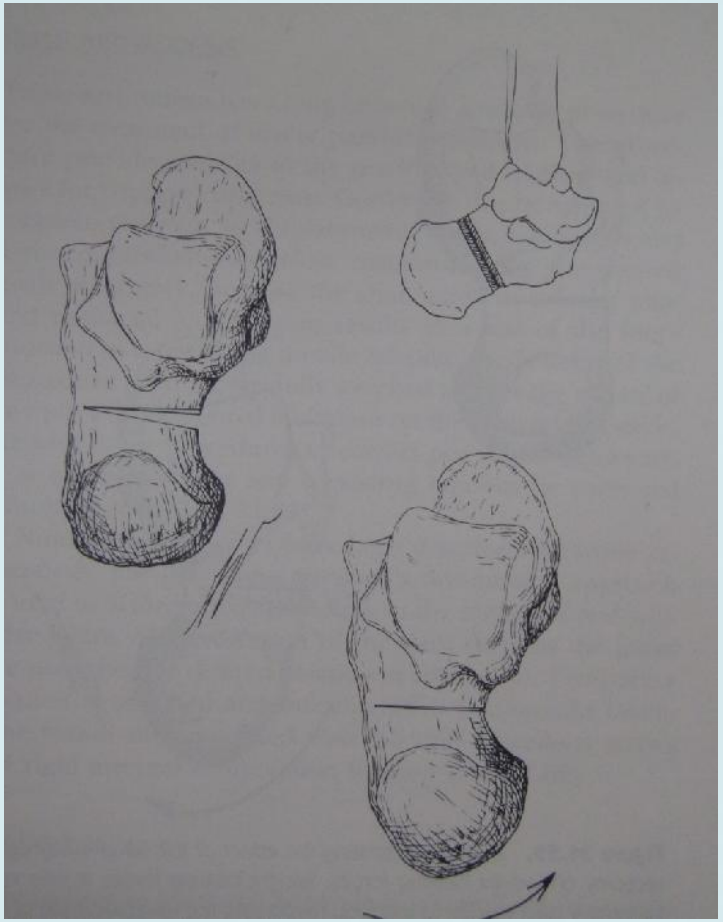

Pes Planus - Calcaneal osteotomy

- Silver: Mid body opening wedge osteotomy
- Frontal plane correction
- Increases supinatory force of the achilles

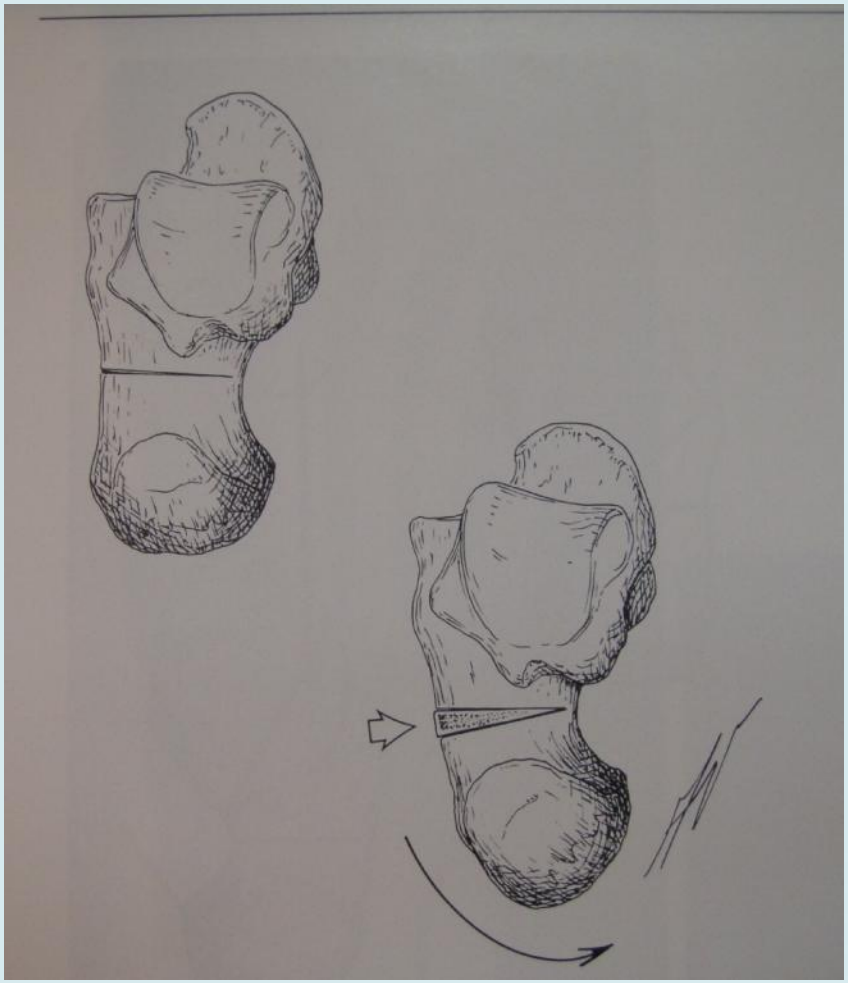

Pes Planus - STJ procedures

- Extraarticular Chambers (sinus tarsi grafting)
  Baker-Hill (Posterior facet grafting)
  Selakovich (Sust tali grafting)

- Arthroeresis Many prostheses available
  - Limit frontal plane motion

Pes Planus - Subtalar Joint Procedures

- Arthroeresis: Limits frontal plane motion
  - Advance to midline of the talar neck

Sample Question

- 12 yo male with achy feet
- PMH, Meds, Psxhx

unremarkable

- PE:BMI 34, -5 deg talocrural dorsiflexion, flexible pes planus
- Imaging

Question Cont'd

- Film interpretation?
- Treatment options?

Cavus Foot

The Goldfarb Foundation

Cavus Foot - Etiology

- Congenital:
  - Spina Bifida
  - CMT
  - Roussy-Levy Syndrome
  - Frederich's Ataxia
  - CP
  - Clubfoot
  - Syphilis
- Acquired:
  - Poliomyelitis
  - Trauma
  - Lederhose disease
  - Spinal Cord Tumors

The Goldfarb Foundation

Cavus Foot

- Classified based on apex of deformity
- Metatarsus Cavus– apex at Lisfranc's
- Lesser Tarsus Cavus – apex at lesser tarsus
- Forefoot cavus – apex at Chopart's
- Combined anterior cavus
- Rearfoot cavus – relative to forefoot

Cavus Foot

- Identify rigidly plantarflexed first ray – Coleman block test
- Images A&B demonstrate a hindfoot varus that is compensatory due to rigidly plantarflexed first ray

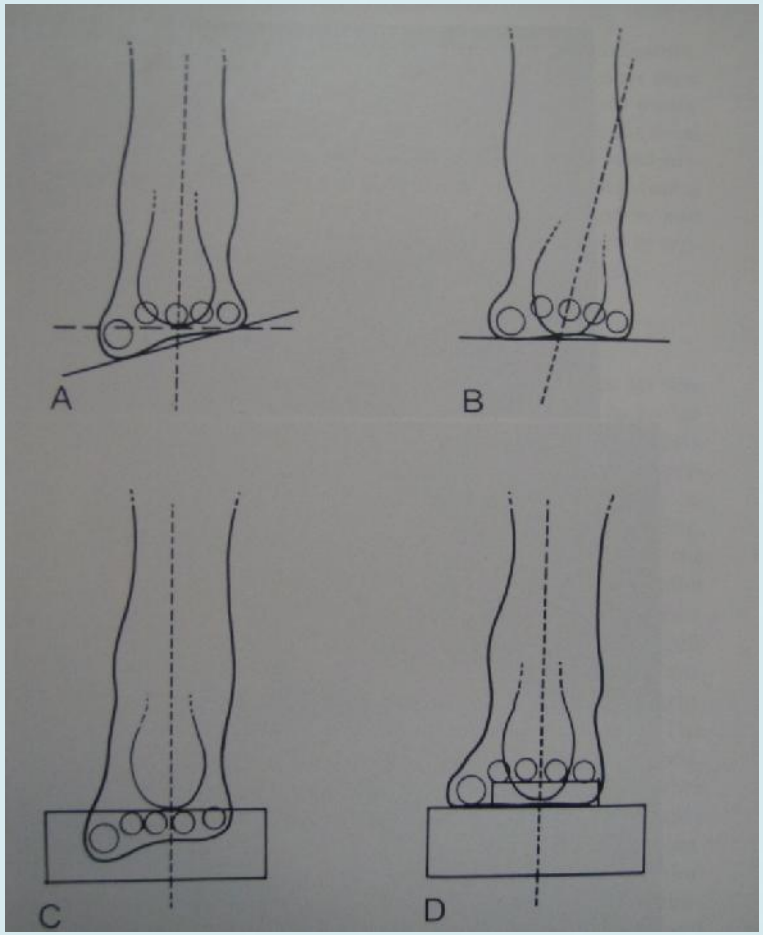

Cavus Foot – Surgical Considerations

- Apex of the deformity
- Rigid versus flexible deformity
- Growth plates
- Progression of deformity – staged procedures?

Cavus Foot - Soft tissue procedures

- Steindler Stripping calcaneal release of:
  - Plantar fascia
  - Abductor hallucis
  - FDB
  - Abductor digiti quinti
- Release of the long plantar ligament from the c-c joint

Cavus Foot – Tendon Transfers

- Principles of Tendon Transfers:

For flexible deformities or to act as a strut?

Muscle will lose 1 grade of power

Clear channel for tendon transfer and excursion

Post operative PT – train out of phase muscles

Cavus Foot – Tendon Transfers

- Transferring tendons from the digit to the metatarsal eliminates digital buckling and retrograde force from the digit
- Jones Tenusospension: EHL to 1st met neck
- Heyman Procedure: Extensor to respective metatarsal neck
- Hibbs: Extensors to the lateral cuneiform

Cavus Foot – Tendon Transfers

- STATT: Lateral tibialis anterior anastamosed to the peroneus tertius
- Peroneus longus tenson transfer:

PL transected at the cuboid, passed down the EDL sheath and attached to the lesser tarsus.

- PTT Transfer: PTT through the interosseous membrane, passed down the EDL sheath and attached to the lesser tarsus

Cavus Foot – Midtarsal Osteotomies

- Cole: dorsal closing tarsal wedge

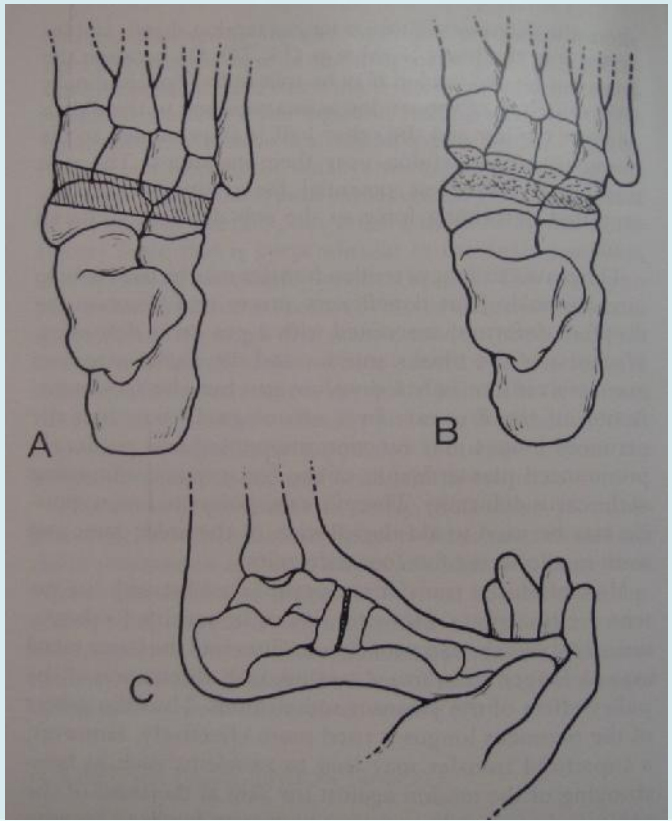

Cavus Foot – Midfoot Osteotomies

- Cole:

Adjunctive procedures: plantar fasciotomy/Steindler stripping, digital alignment

Additional 1st ray procedures prn

Disadvantages: shortens the foot

Cavus Foot – Midtarsal Osteotomies

- Japas:midatarsal V osteotomy with apex proximal, lateral arm through the cuboid, medial arm through the medial cuneiform

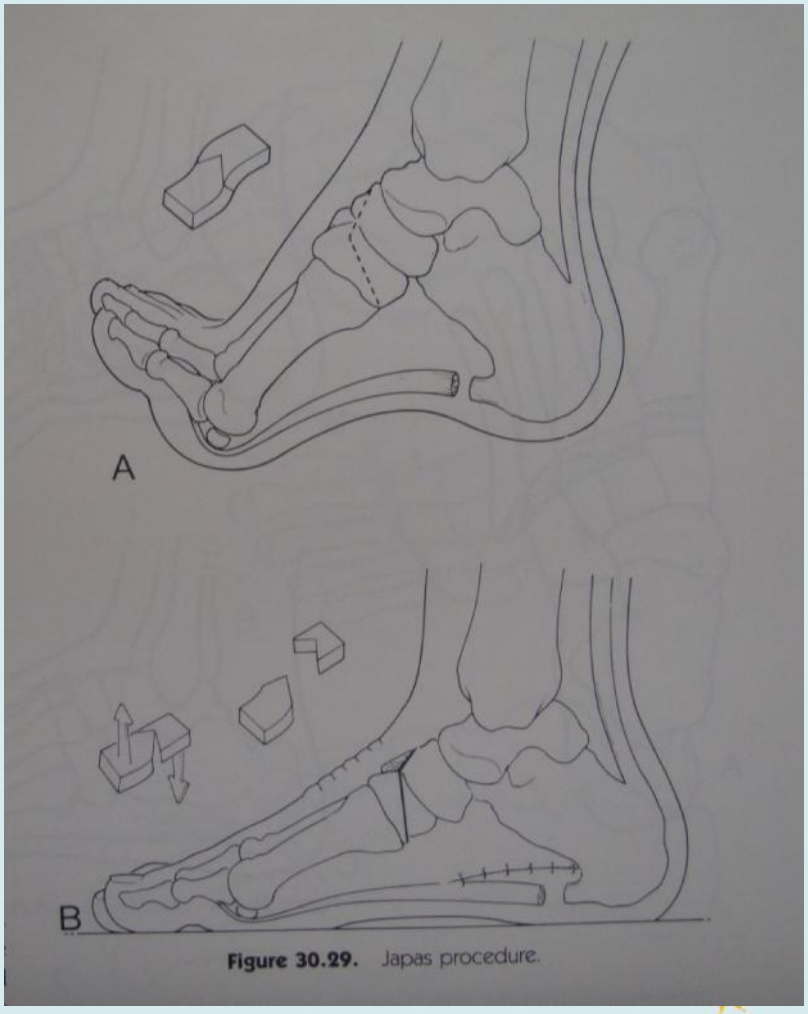

Figure 30.29. Japas procedure.

Cavus Foot – Midtarsal Osteotomy: Dorsiflexory truncated Lisfrac arthrodesis

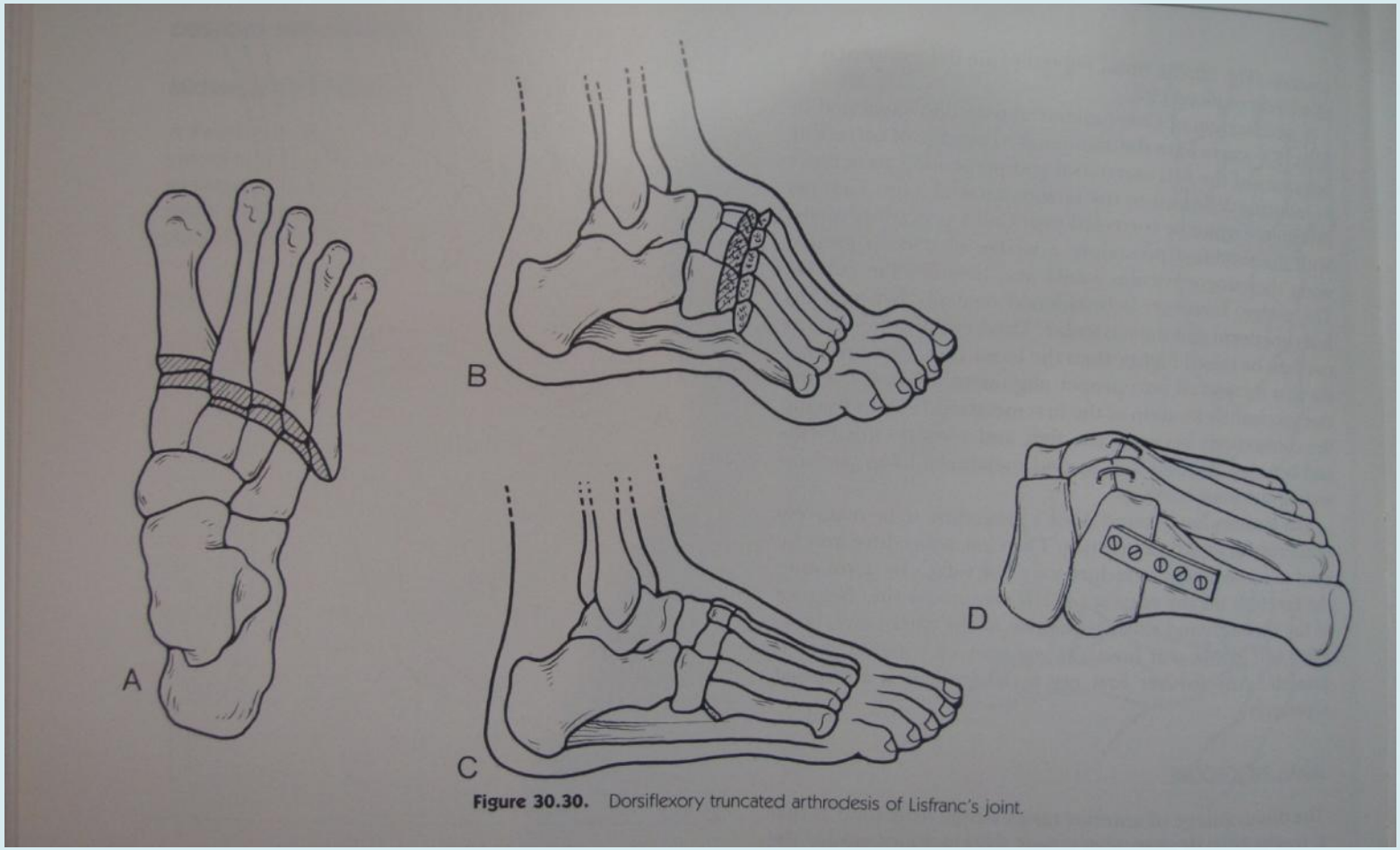

Figure 30.30. Dorsiflexory truncated arthrodesis of Lisfranc's joint.

Cavus Foot – Metatarsal Osteotomies

- Multiple dorsiflexory metatarsal osteotomies:

Periarticular - Avoids lesser tarsus trauma and resultant arthritis

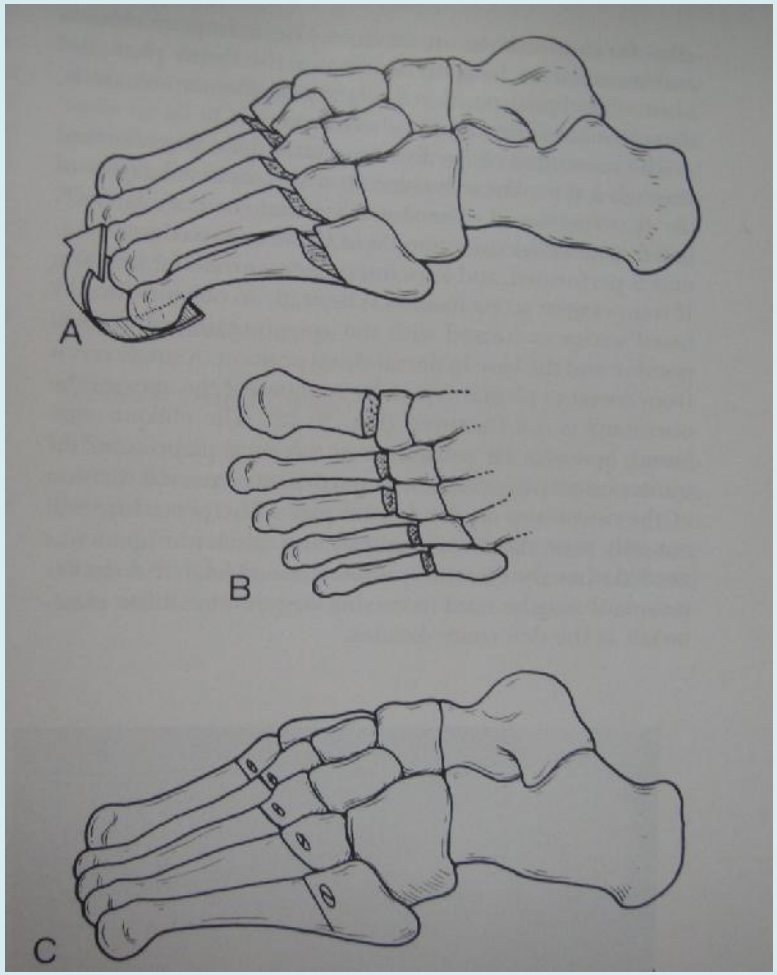

Cavus Foot – Calcaneal osteotomy

- Dwyer: Mid body closing wedge osteotomy
- Lateral base wedge

for cavus foot

Rearfoot Arthodesis

- Subtalar
- Triple Arthrodesis – T-N, C-C, STJ
- Indications: Severe DJD, severe triplane deformity with pain, paralytic deformity, or for long-standing rupture of the tibialis posterior, with collapse of the foot

Triple Arthrodesis

- Fusion of the talonavicular, calcaneocuboid and subtalar joints
- Denude MTJ then STJ, fixate STJ the MTJ

Triple Arthrodesis

Lateral Incision:

- Avoid sural, IDC nerves, peroneal tendons
- Evacuate sinus tarsi, reflect EDB
- Transect interosseous talocalcaneal and calcaneo fibular ligaments
- Expose posterior STJ, CCJ, lateral TNJ

Medial Incision:

- Midway between tibialis anterior and posterior
- Avoid saphenous vein,nerve

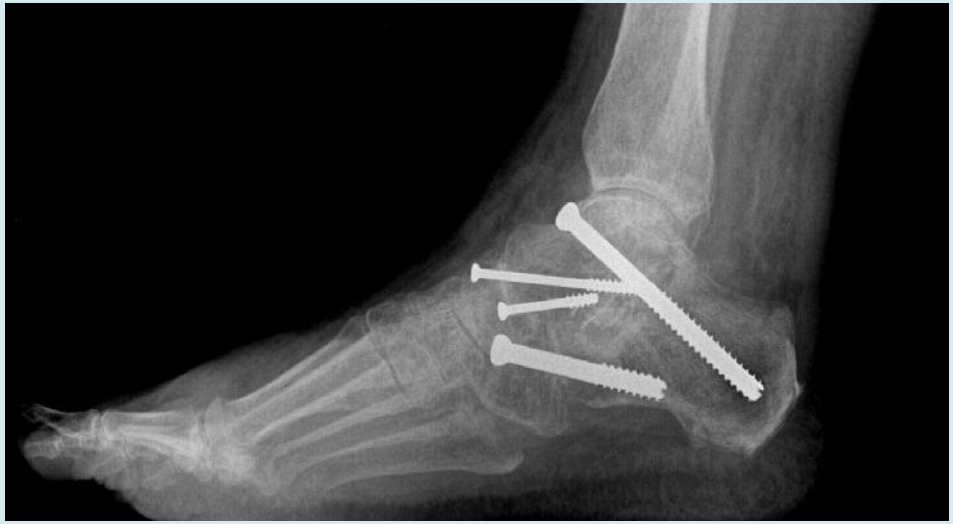

Triple Arthrodesis

- Position rectus to mild valgus
- Anterior talar translation plantar flexes the foot
- Deformity correction with wedge resection and bone grafting (ex. C-C graft in pes plano valgus, wedge resection in pes cavus)

The Goldfarb Foundation

Double Arthrodesis

The Goldfarb Foundation

Triple arthrodesis - Postoperative management:

- Jones compression cast/splint 2-3 days
- Drain pulled at 48-72 hours
- A B-K NWB cast is applied for 6-12 weeks
- Take serial x-rays to evaluate healing
- B-K WB cast is then used for 4 weeks
- Physical therapy continued for 3 months
- Goal is a return to normal function 6 months postoperatively

Triple Arthrodesis

Complications:

- Fracture
- Wound dehiscence
- Peroneal tendonitis
- Entrapment neuropathy
- Nonunion/malunion
- Anterior ankle jamming: equinus, aggressive posterior STJ resection, plantarflexed forefoot, screw placement
- Under/over correction

Postoperative gait pattern:

- Abducted gait
- Shorter stride
- Difficulty in going down stairs

Ankle Pain

- Differential diagnosis: Intra versus extrarticular
- Diagnostic tools: Xrays
  - Stress Xrays
  - Arthrocentesis
  - MRI
  - CT
  - Bone Scan
  - Arthroscopy

Chronic Instability

- Mechanical vs functional
- Proprioception-single limb stance
- +anterior drawer
- +stress radiographs – 15 decanewtons of force

Chronic Lateral Ankle Instability

- Mechanical instability – diagnose with Telos, clinical exam, MRI
- Functional instability – diagnose with history
- Assess hindfoot position and consider Dwyer for calcaneal inversion

The Foundation

Telos and stress Xrays

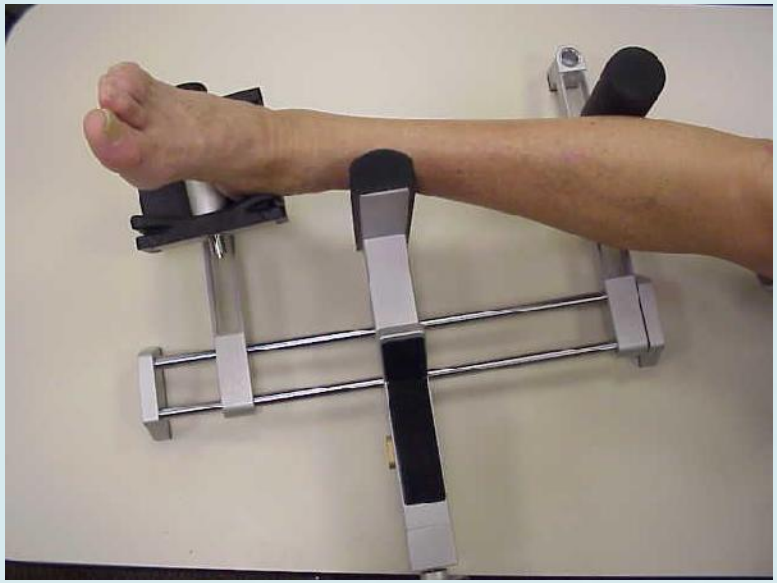

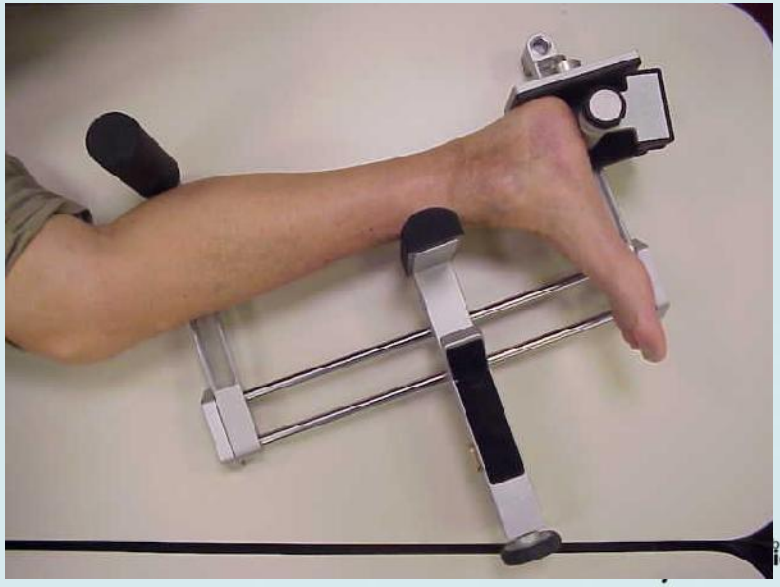

Stress Radiograph Evaluation

The Goldfarb Foundation

Lateral Ankle Stabilization

- Repair of ATFL and/or CFL
- Brostrum: primary ATFL repair
- Peroneus Brevis (Watson-Jones, Lee, Evans, Nilsonne, Christman Snook, Whinfield
- Plantaris (Kelikian)
- Peroneus Longus (Hambly, Seeburger)
- Allograft for anatomic recreation

Lateral Ankle Stabilization

- Post Operative Course:
  - Cast, NWB 2-4 weeks
  - WB in cast
  - PT – focus on peroneal strength and reaction time, proprioception

Ankle Arthroscopy

- Indication:
  - Synovitis
  - Instability
  - OCD
  - Diagnosis
- Contraindications:
  - Infection

Ankle Arthroscopy

- Insufflate
- Portals: Antero medial – avoid tibialis
- anterior, greater saphenous

  Anterolateral – avoid peroneus

  tertius, IDCN, lateral talar wall.
- Fluids – lactated ringers – pump?
- Distractor?
- Scope 2.7 or 4mm 30 degrees

Arthroscopic - diagnosis

Hyperthrophic synovitis

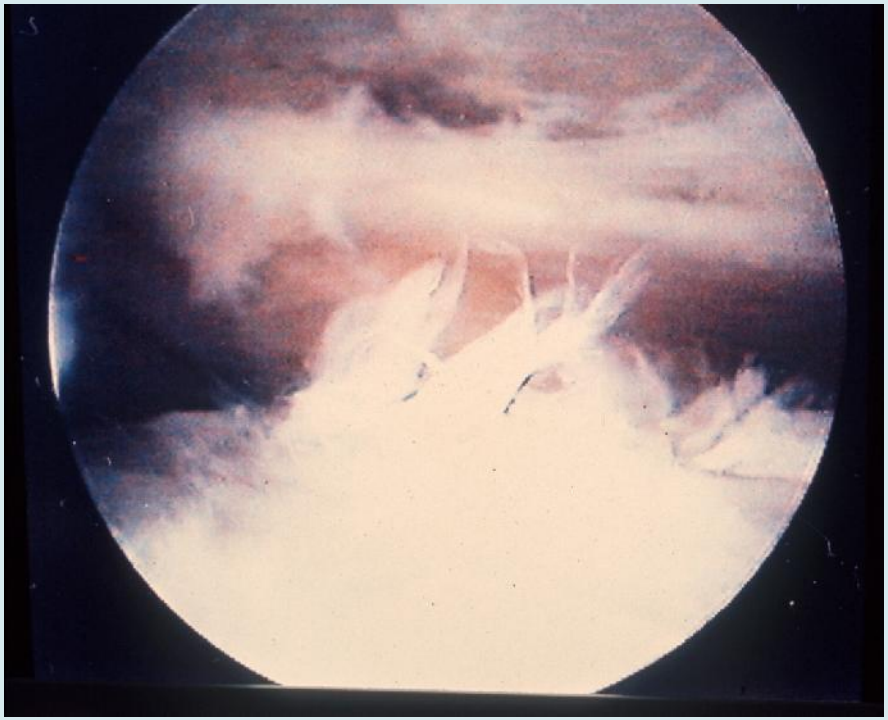

Hemmorhagic synovitis

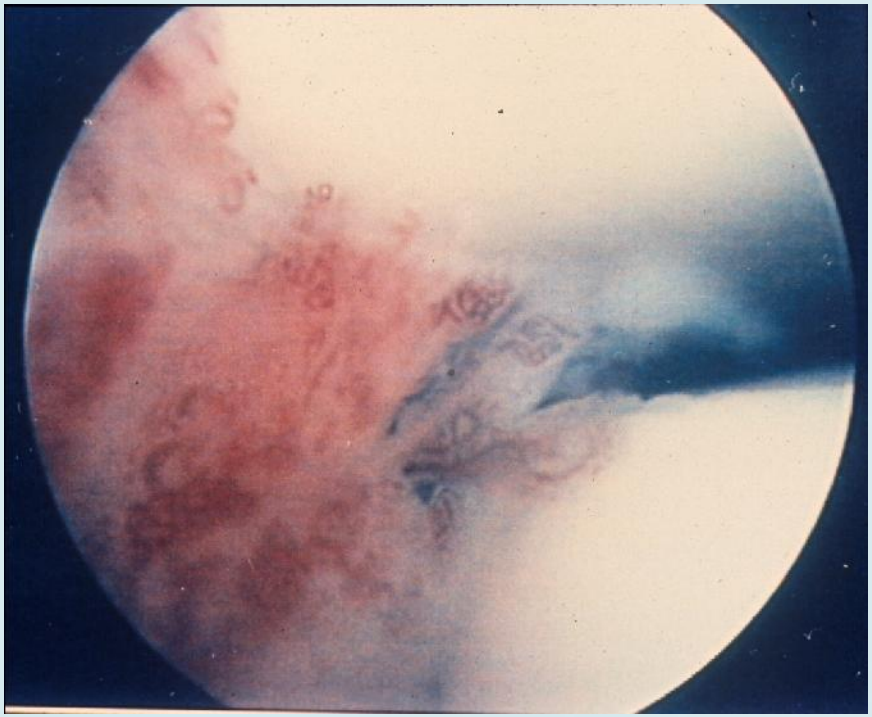

Arthroscopic diagnosis

- Ankle instability:
  - With rearfoot inversion PTFL in visualized in posterior lateral gutter

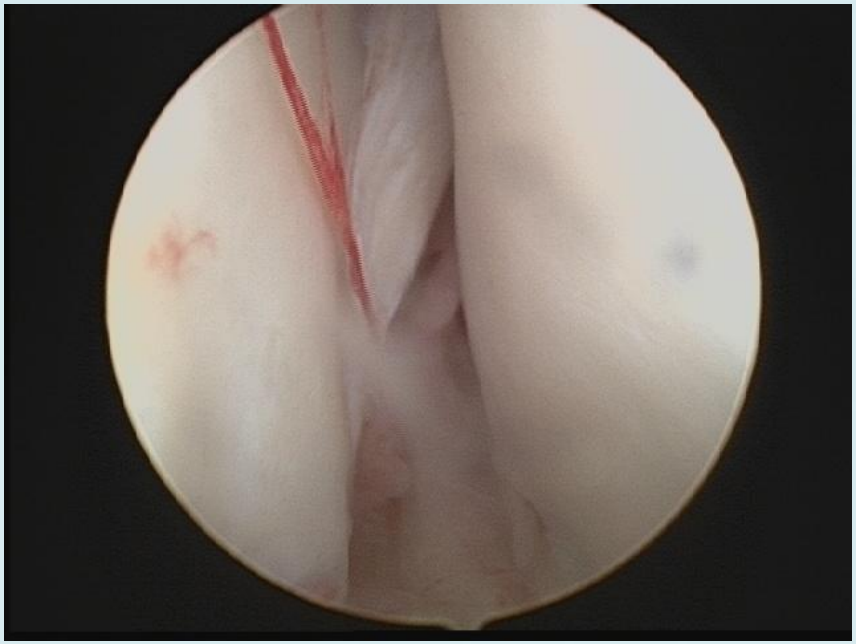

Arthroscopic diagnosis

- Lesion visualized on shoulder with crabmeat fibrillation
- Postero medial talar lesions most common due to frequency of plantarflexion inversion ankle sprains

Arthroscopy diagnosis

Osteochondral defect

- S/S difficult to isolate pain
- Unresponsive to typical conservative treatment
- Pain with axial impact
- Dx: arthrocentesis/block

  MRI

  Arthroscopy

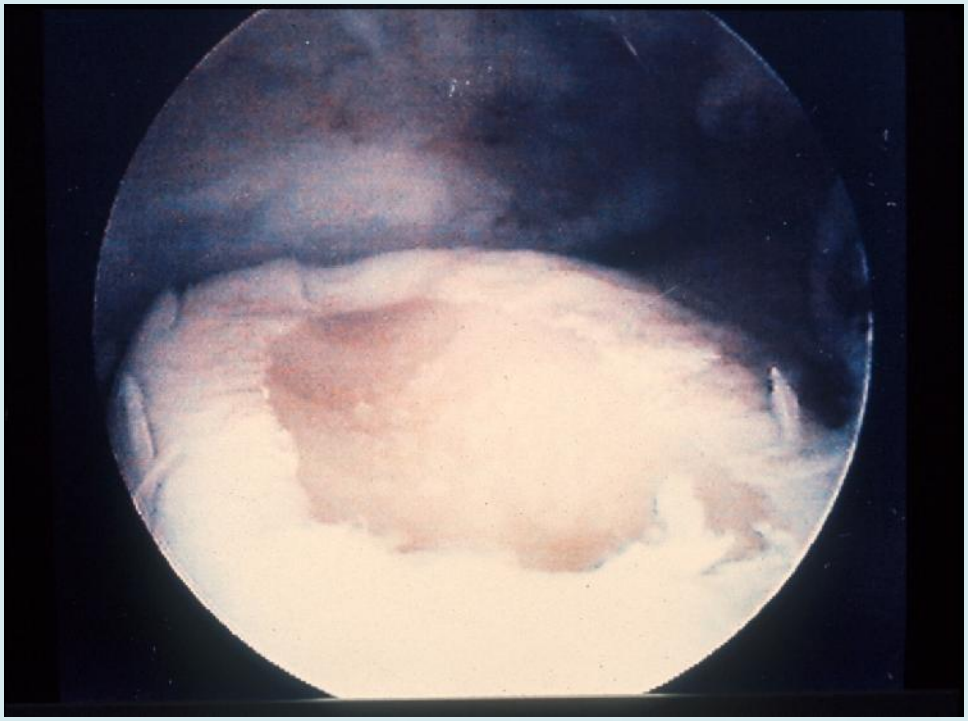

Arthroscopy – Post operative course

- Early ROM
- PT
- Steroid infiltration
- Immediate WB? – pending adjunct procedures

Arthroscopy - complications

- Nerve entrapment
- Vascular embarassment
- Cartilage damage
- Hemearthrosis
- Arthrofibrosis – diagnose with MRI

OCD - TREATMENTS

- Cast, NWB
- Arthroscopic debridement with micro fracture (fibrocartilage) – BMA with fibrin glue
- Mosaicplasty
- OATS (hyaline cartilage)
  - Indications:
    - Chronic pain
    - Failed microfracture
    - Lesion >1cm, shoulder/uncontained

The Foundation

OCD - access

- Run guide wires/screws
- Chevron malleolar osteotomy – power/osteotome fracture
- Flip med mall inferiorly on deltoid

OATS

- Fresh Allograft:
  - Provides viable chondrocytes
  - Prevents donor site morbidity
  - Matches contour of recipient's bone
  - Matches cartilage thickness (1.0-1.6mm)
  - Risk of disease transmission 1 per 1 million

The Gold farb Foundation

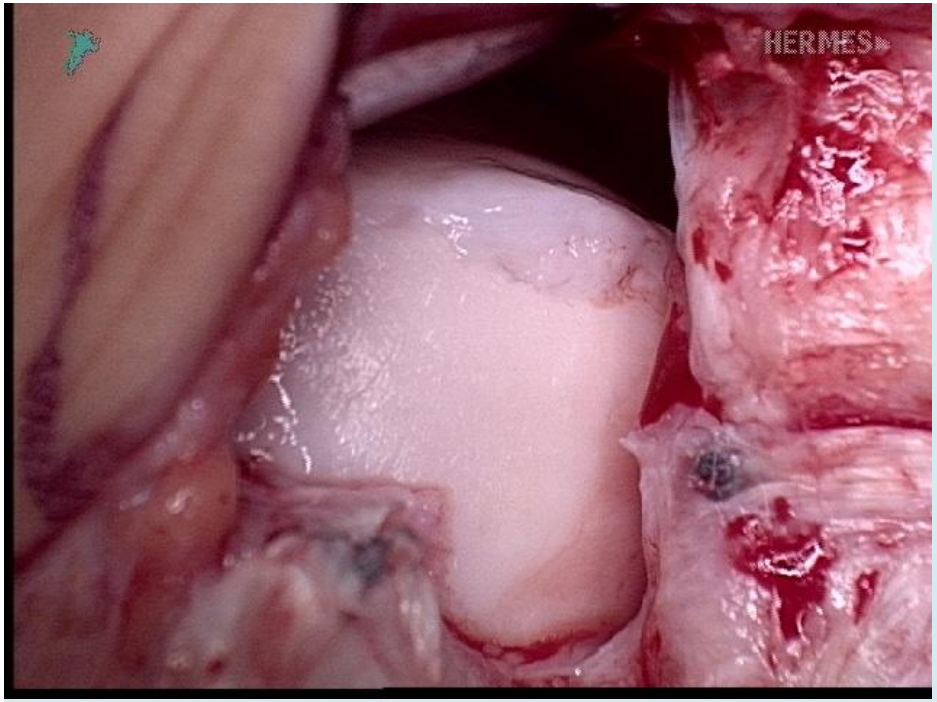
HERMES

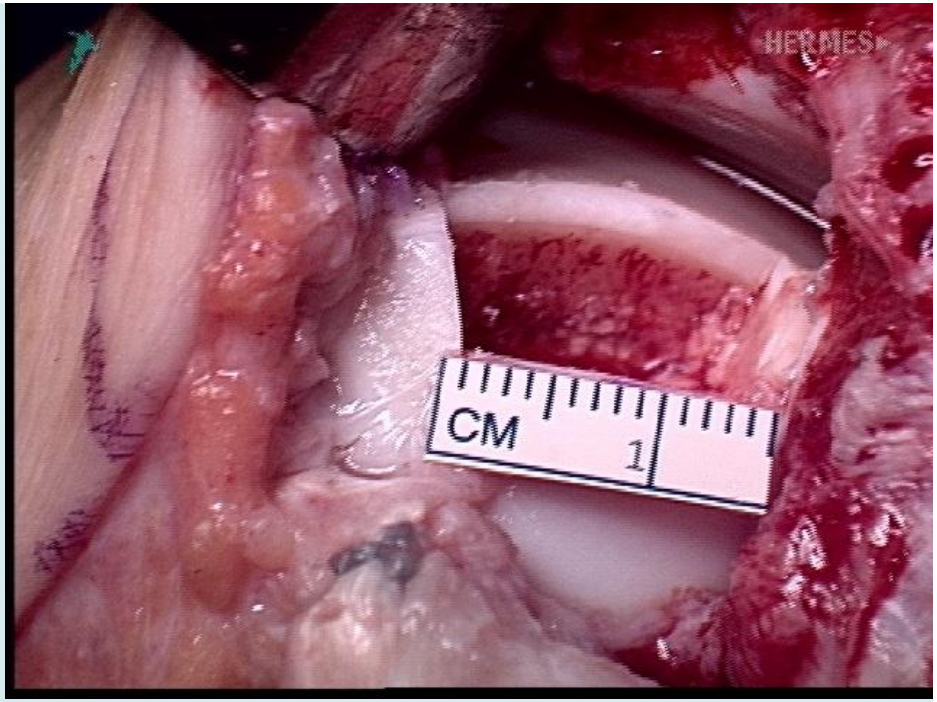
HERMES
CM
1

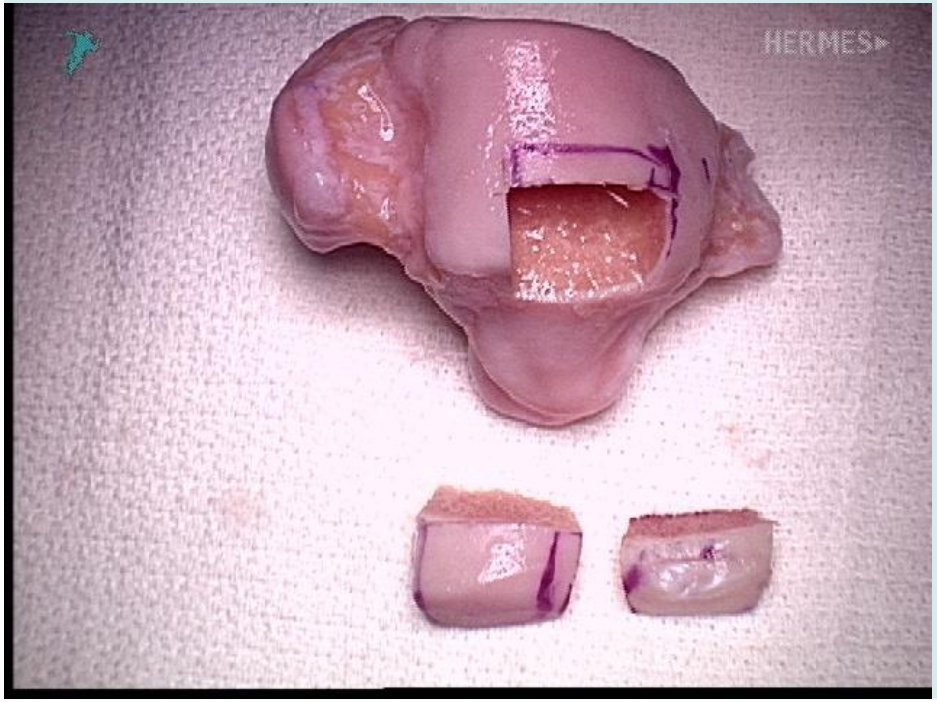
HERMES

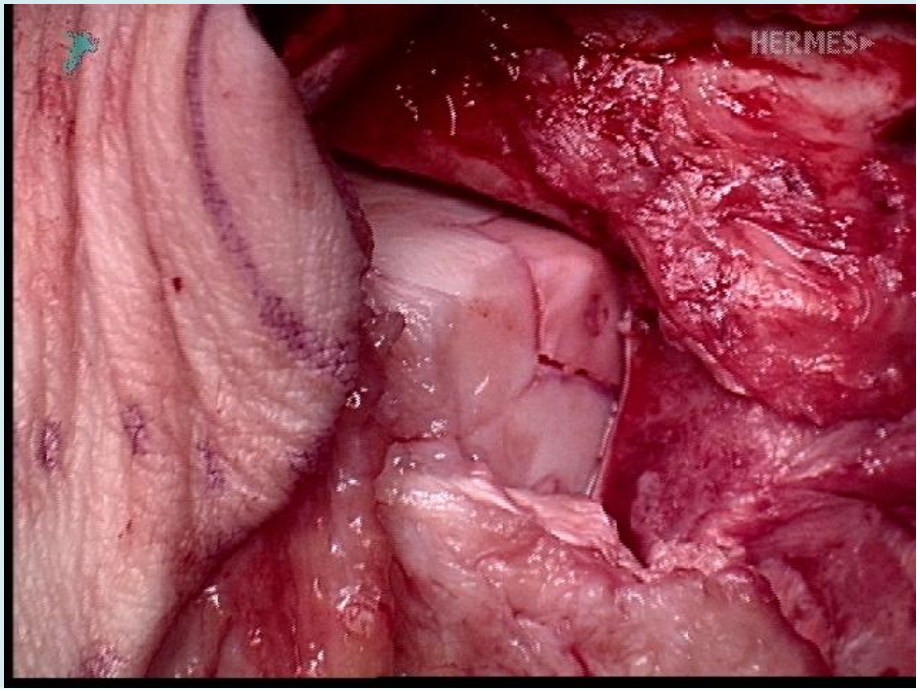
HERMES

OATS

- Adjunct procedures: Lateral ankle stabilization
- Post operative course
  - 6-8 weeks NWB
  - Post operative PT
- Complications:
  - DJD
  - Arthrofibrosis
  - Infection, nerve entrapment, malleolar nonunion

Sample Board Question

- 52 yo Female with chronic ankle pain
- Hx: multiple B/L ankle sprains
- PMH, Meds, All noncontributory
- PE
- Imaging – xrays, stress? MRI
- Arthrocentesis

The Goldfarb Foundation

Sample board question – Cont'd

- Dx: Instability LT, Instability and OCD RT
- Treatment Options
  - Stabilization LT, OCD repair RT
- Post op course

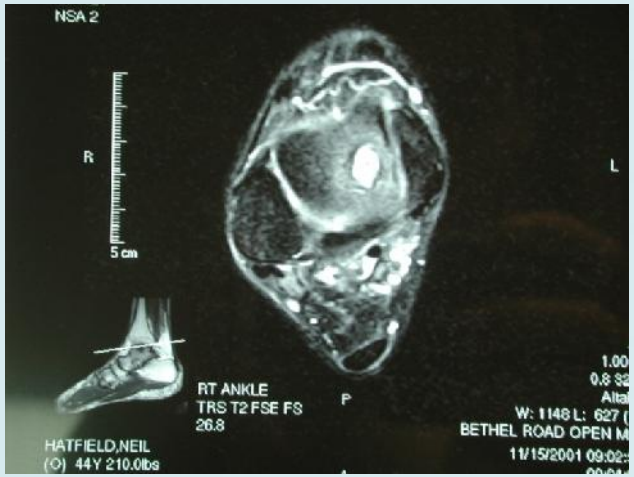

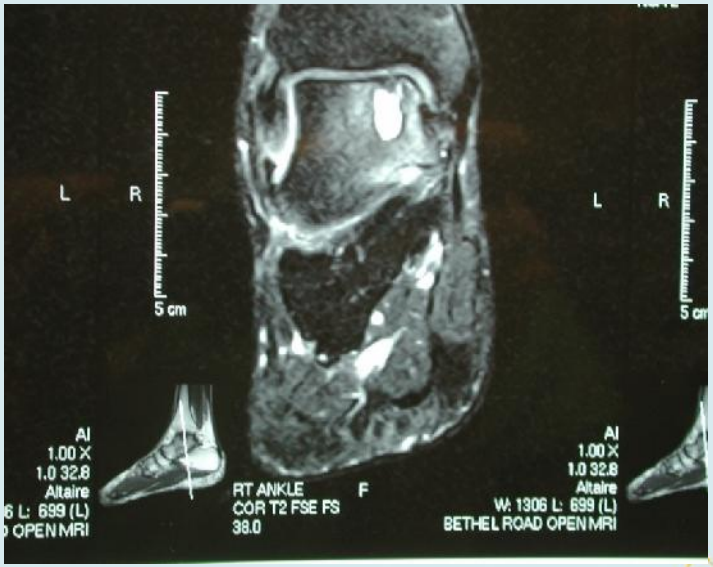

Ankle Arthrodesis

- Indications: This procedure is indicated primarily in patients with severe pain and deformity, Including: DJD, RA, talar collapse, failed ankle joint prostheses, infection of the ankle joint, drop foot, invasive tumors, and congenital deformities
- Can be combined with triple arthrodesis if tarsal arthroses noted - pantalar arthrodesis

Ankle Arthrodesis - Surgical approaches:

- Midline longitudinal anterior approach: Between TA and EHL
- Lateral approach via hockey-stick incision: When combined with a fibular osteotomy this approach gives good exposure of the posterior, lateral, and anterior aspects of the ankle
- Medial malleolar approach: When combined with medial malleolar osteotomy gives good exposure of the anteromedial, medial, and posteromedial aspects of the ankle joint

Surgical technique categories:

- Articular wedging with or without grafting
- Anterior arthrodesis with inlay grafting
- Articular wedging combined with malleolar osteotomy
- Dowel or other subtotal fusions
- Compression arthrodesis

The requirements for a successful fusion:

- Complete removal of all the cartilage, fibrous tissue, and any other material that may prevent contact of raw bone to raw bone
- Accurate and close fitting of the fusion surfaces
- Optimal position of the ankle joint - 0 deg dorsiflexion, 5 deg valgus, 10 deg ext rot, posterior translation of the talus

Fixation

- Standard screw fixation
- Monorail fixator
- Fusion rods
- Circular external fixator

When combined with STJ fusion:

- Plate
- Retrograde intramedullary nail

Ankle Arthrodesis – Complications

- Non union
- Malunion
- Adjacent joint arthritis
- Neuritis
- BKA

The Goldfarb Foundation

External Fixation

- Know basic principles and instruments
- Circular, unilateral, hybrid
- Variety of hinges, threaded rod connectors, olive wires, different shaped rings, clamps, foot plates allow infinite configurations
- Compression versus stabilization

Ex Fix Components

- Unilateral fixator
- Closer to bone is more stable
- Half pins – threaded
- Bury threads to minimize soft tissue irritation from pistoning

Ex Fix Components

- Circular rings
  - Increase options for entry/exit points
- Can use half pins or wires
- Pin insertion: pierce soft tissue, drill through bone, tap through soft tissue

Ex Fix Components

- Hybrid
- Wire tensioning can provide compression:
  - Russian or tensiometer

The Goldfarb Foundation

Ex Fix - Advantages

- Ability to be adjusted during the healing phase
- It is only a temporary device – osteomyelitis
- Rigid fixation with ready access to soft tissues for debridements and dressing changes
- Neighboring joint motion can be preserved
- Dynamization to stimulate neovascularization
- Arthrodiastasis

Ex Fix Disadvantages

- Pin Tract infection
- Pin Loosening
- Patient acceptance
- Patient compliance +/-
- Maintenance
- Cost

Ankle Replacement – a brief history

- Early failures in the 70's – difficult mechanics
- US trials since the early 80's
- FDA approval
  - De Puy Agility
  - Wright InBone, Infinity
  - Tornier Salto Talaris
  - Kinetikos Eclipse
  - SBi STAR
  - Zimmer Trabecular Metal Total Ankle
  - Cadence

Ankle Replacement

- Indications
  - DJD (OA, RA)
  - Adjacent joint DJD
  - Age 50-60+yrs old
  - Activity – moderate/low impact
  - Alignment – correct prior to TAR
- Contraindications
  - Comorbidities
  - Age
  - Activity – high impact
  - Obesity (250lbs)
  - Non correctable deformity
  - Peripheral neuropathy
  - AVN
  - Malleolar abscence

TAR Prostheses

- Three component titanium cobalt tibial and talar components with porous coating for bony ingrowth
- Noncemented ?
- HMWPE meniscal bearing
- Fixed bearing: Agility, Salto Talaris, InBone, Zimmer, Cadence
- Mobile bearing:STAR

TAR prostheses

- Agility – medial fibular weight bearing with syndesmotic fusion, small talar component prone to subsidence
- InBone – Intramedullary guidance, modular tibial stem, good salvage option
- Zimmer – Lateral transfibular approach
- STAR – non constrained mobile bearing, FDA approved non cemented

The Goldfarb Foundation

TAR

- Anterior incision – between TA and EHL
- Common adjunct procedures:
  - -TAL
  - -Lateral ankle stabilization
  - -Deltoid lengthening
  - -Hindfoot arthrodesis
  - -Supramalleolar osteotomy

Ankle Replacement – post operative course

- 1-2 days in house
- Wks 1-2 cast NWB
- Wks 3-4 cast introduce WB
- Wks 4-5 removable cast boot
- 2-3 months Physical Therapy

The Goldfarb Foundation

Agility

Salto Talaris

STAR

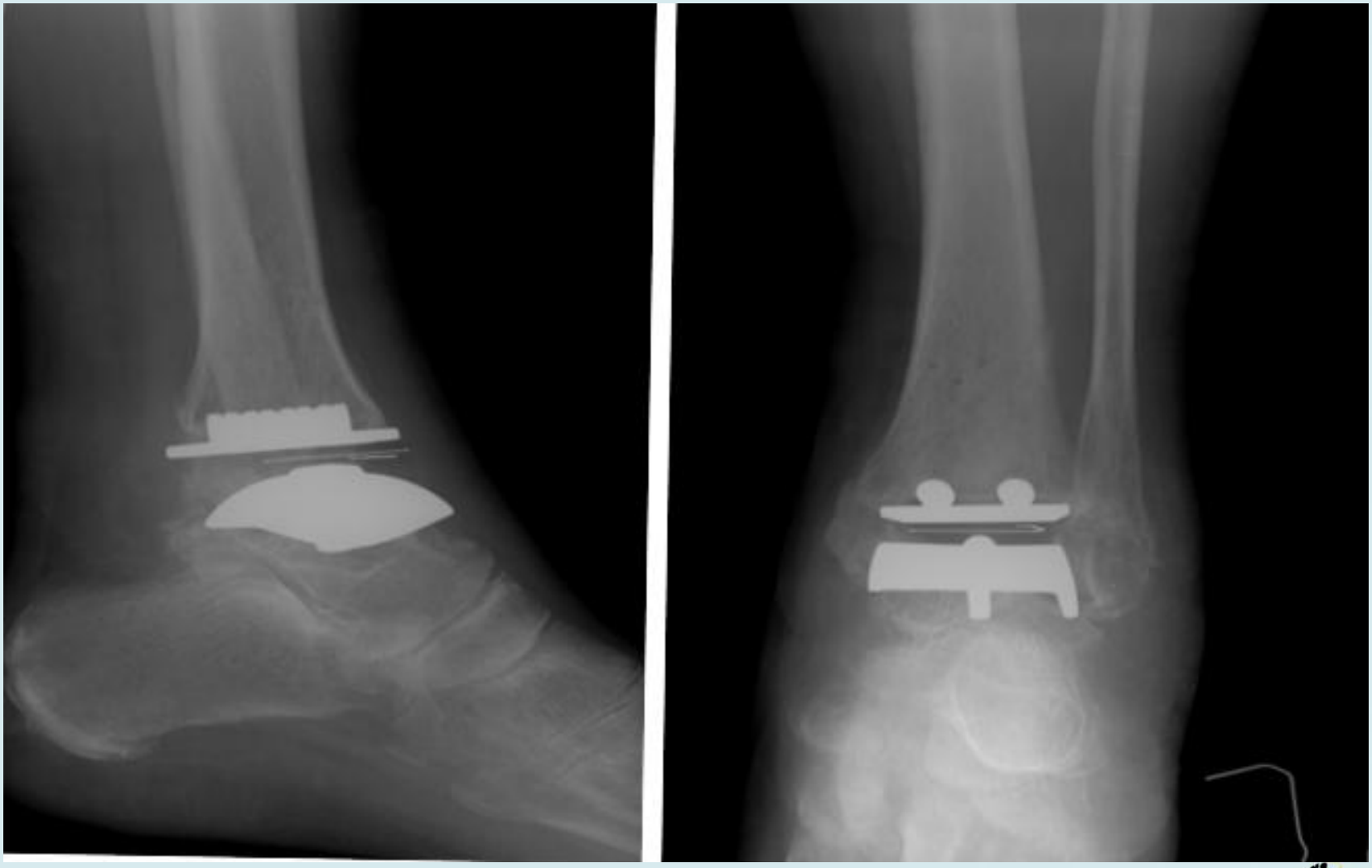

The Goldfarb Foundation

Prophecy Intraop Guidance

Infinity

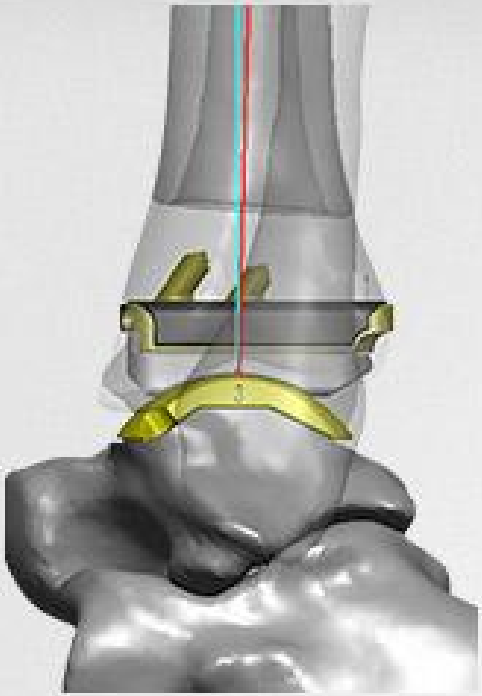

PROPHECY®
Preoperative Plan

Postoperative
X-ray

The Goldfarb Foundation

InBone

TAR Complications

- Skin slough/dehiscence
- Malleolar fracture
- Malalignment
- Polywear
- Bony lysis, cyst formation
- Subsidence
- Frank failure
- BKA

Peri prosthetic lysis

- Post operative surveillance with plain films and CT
- Treat prosthetic loosening with prosthesis exchange
- Curette and graft cysts

Sample Question

- 67 yo male with talocrural arthritis
- PMH: unremarkable
- PE: pain, crepitus, limited ROM ankle, no deformity
- Imaging: Xray, CT/MRI

Question Cont'd

- Treatment – TAR
- Post op course – NWB with early ROM
- Failure - subsidence
- Salvage – conversion to fusion – void fillers

Pantalar Arthrodesis

- Tibiotalarcalcaneal arthrodesis
- Salvage post failed ankle arthrodesis, talar AVN, TAR, vertical talus

Pantalar Arthrodesis

- 1 incision-lateral hockey stick
- 2 incisions-anteromedial and lateral hockey stick
- Denude to bleeding cartilage

Pantalar arthrodesis

- Alignment
  - Displace talus posteromedially on tibia
  - 0 degrees dorsiflexion sagittal plane
  - rectus to mild valgus frontal plane
- Bony defect–2cm shortening acceptable

  - consider autograft struts
  - allograft (femoral head for TAR)
  - Biofoam wedges

The Goldfarb Foundation

Pantalar Arthrodesis - fixation

- Screw fixation for primary fusions – less vascular disruption and higher fusion rates?
- IM rod, plating, EX fix for salvage
- Intramedullary rods
  - Medial talar displacement allows easier guide pin and rod placement
  - Over ream rod size by 1mm.
  - Chatter = cortical contact
  - Compression – static on the table, back slap or dialed in

Pantalar arthrodesis

- Slow healing, slower with larger defects – creeping substitution
- Compression with Ex fix, dynamize IM nails
- Rocker bottom shoes post op

Supramalleolar Deformity

- Must be identified when dealing with pedal pathology and selecting procedures
- Long leg axial films
- Tibial recurvatum linked to talocrural DJD
- Genu valgum linked to PTTD

Supramalleolar deformity

- Frontal Plane Mechanical Axis of the Lower Limb - Static weightbearing axis which can be drawn on a radiographic image of the limb. It is the line drawn from the center of the femoral head to the center of the ankle joint. Normally passes just medial to the center of the knee joint.
- Mechanical Axis Deviation - the perpendicular distance from the middle of the knee joint the mechanical axis line in the AP and Frontal plane in millimeters.

Supramalleolar osteotomies

- Crescentic corticotomy at the apex of the deformity
- Percutaneous drill holes then connect the dots with an osteotome
- Static fixation – screws, plates
- Ex fix – allows adjustment

Supramalleolar osteotomies

- Adjunct procedures:
  - -Fibular osteotomy – consider if deformity >15-20 degrees
  - -TTR – consider with procurvatum and varus deformities

Good Luck!

The Goldfarb Foundation